

CASE REPORT: POST-MEGASTENT DUODENAL POLYP

Mohammed Omer Mohammed ^a, Araz Latif Raheem ^b, and Ali Jabbar Ahmed ^c



Submitted: 24/2/2022; Accepted: 15/7/2022; Published: 21/9/2022

INTRODUCTION

Most duodenal polyps are non-neoplastic. Instead, they represent regenerative/hyperplastic nodules of foveolar epithelium or Brunner gland proliferation (38%). Other less common polyps include heterotopic (6%) and neoplastic lesions (11%)⁽¹⁾. Adenomas of intestinal type are the most common (89%), followed by adenomatous lesions that present a gastric phenotype: PGAs (8%) and foveolar-type adenomas (3%)⁽²⁾.

Non-neoplastic duodenal polyps, most of which represent regenerative inflammatory (pseudo) polyps, are predominantly localized in the bulb (80%)⁽¹⁾. The majority are associated with duodenitis, especially in the setting of peptic injury, and are less commonly associated with inflammatory bowel disease or rare conditions such as primary immunodeficiencies.⁽³⁾ Histologically, non-neoplastic duodenal polyps may resemble gastric hyperplastic polyps and frequently show metaplastic foveolar epithelium with active inflammation and/or erosion, reactive epithelial changes, seamless transition with the surrounding epithelium, and surface maturation. They may also simply be composed of granulation tissue. It is worth underscoring that some of these polyps are neoplastic. Some hyperplastic polyps harbor KRAS and BRAF mutations and tend to show serrated features, similar to their microvascular colonic counterparts⁽⁴⁾. Duodenal hyperplastic polyps with KRAS mutation may represent precursor lesions of duodenal traditional serrated adenomas⁽⁴⁾. The polypoid heterotopic gastric mucosa is another frequent type of duodenal polyps. As opposed to the peptic injury-induced foveolar metaplasia, lesions of this type also contain clusters of oxyntic glands under the surface of the foveolar epithelium. Duodenal gastric heterotopia is associated with FGPs and PPI therapy.

Keywords: *Megastent, Duodenal polyp.*

^a College of Medicine, University of Sulaimani, Kurdistan Region, Iraq.

^b Gastroenterology and Hepatology Teaching Hospital, Sulaimani, Kurdistan Region, Iraq.

^c KBMS board trainee, Gastroenterology and Hepatology Teaching Hospital, Sulaimani, Kurdistan Region, Iraq.

Correspondence: mohammed.raheem@univsul.edu.iq

CASE PRESENTATION

A 24-year-old morbidly obese (BMI 44.3) male underwent a laparoscopic sleeve gastrectomy operation. After two weeks of operation, he developed fever, hematemesis, and melena but no abdominal pain.

On physical examination, he was pale, the temperature was 38.7C, with no jaundice, no tenderness, and no palpable abdominal mass. Admitted to hospital and put on conservative Rx (IV normal saline and IV Ceftriaxone one gram bid), received two units of blood, and was referred to Kurdistan Center for Gastroenterology and Hepatology for OGD. In OGD, there were two sites of perforation, below GEJ at the fundus site, and other parts of the stomach and duodenum were normal. So, a fully covered Taewoong Niti-S™: Mega™ Esophageal metallic Stent (length 23 cm; diameter: body 28mm) was deployed under fluoroscopic guidance with the proximal end in the esophagus and the distal end in suprapapillary position in the second part of the duodenum using a fluoroscopic marker, thus covering the entire stomach sleeve and kept for nine weeks.

After removal of the stent, a proper OGD was repeated and revealed fully sealed both perforation sites. Still, there was a single large pedunculated polyp with a semi-circumferential clean base ulcer near the root of the polyp pedicle in the second part of the duodenum opposite to the papilla of Vater. (Figure 2)

The patient was put on a high dose of proton pump inhibitor (PPI) for two weeks and asked to come for a polypectomy. The polyp was removed successfully under general anesthesia by hot snare piecemeal polypectomy and retrieved and sent for histopathological examination (Figures 3, 4, 5).

The histopathology revealed the polypoidal formation of duodenal mucosa with the underlying proliferation of submucosal fibrosis and smooth muscle proliferation; no myxedematous stroma, neoplastic atypia, necrosis, or mitosis,

morphological features are in favor of non-neoplastic duodenal polyp.

DISCUSSION

Postoperative leaks occur after laparoscopic sleeve gastrectomy (LSG) in 1 %–3 % of cases⁽⁵⁾. Placement of covered metallic stents is an effective treatment strategy^(6,7), but in about 16.9 % of cases, stent migration occurs⁽⁸⁾.

The development of a large pedunculated duodenal polyp over a short period (9 weeks) is unique and strange and seems strongly related to mega stent deployment. Post Stent Placement and/or removal complications include Bleeding, Pain, Perforation, Stent misplacement, ulceration, or migration. However, the development of the duodenal polyp was not mentioned⁽⁹⁾. Up to the authors' knowledge, there were no similar reported cases in the literature.

In conclusion, we recommend doing a proper OGD before laparoscopic sleeve gastrectomy and after removal of megastent; collecting these cases and their details to research the relevance of esophageal megastent deployment with duration, length of the stent, and type(s) of polyps will occur.

Case Report: Post-Megastent Duodenal Polyp

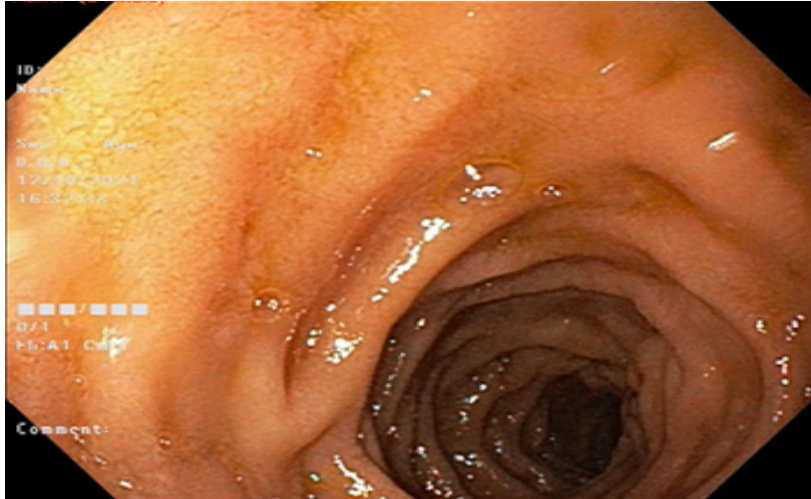

Figure 1. Endoscopic image of the first and second part of the duodenum (D1 & D2) on initial OGD showed no polyp in D2.

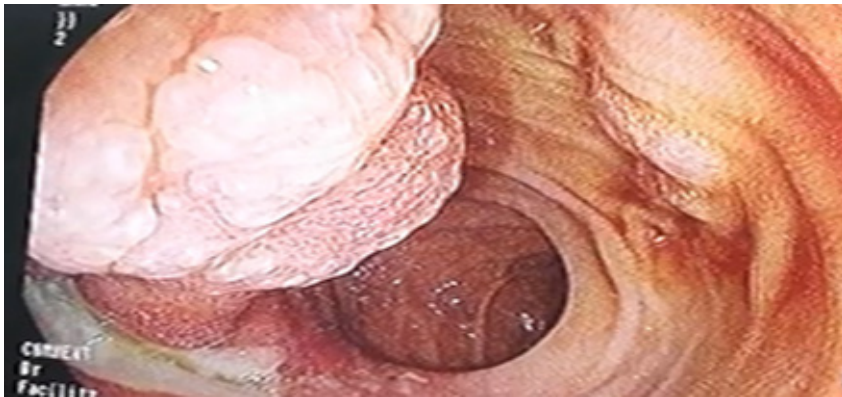

Figure 2. Endoscopic image of duodenum after megastent removal after nine weeks. shows a large pedunculated polyp with clean base ulcer seen on the root of the polyp.

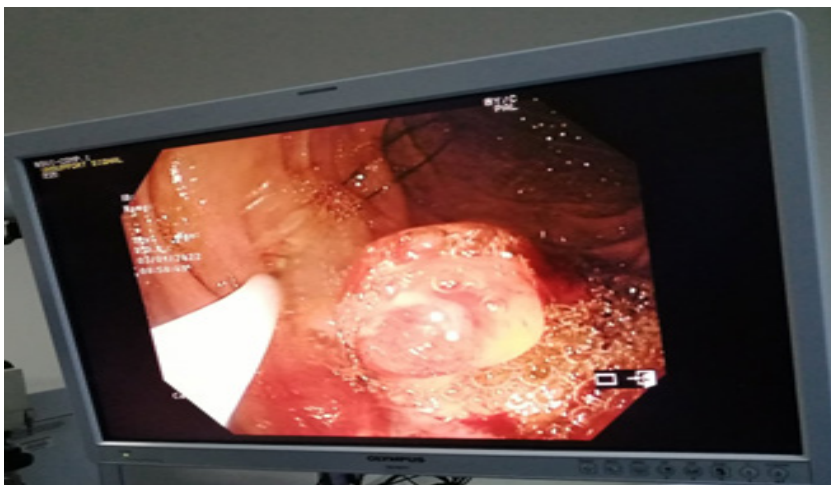

Figure 3. Endoscopic image of duodenal polypectomy.

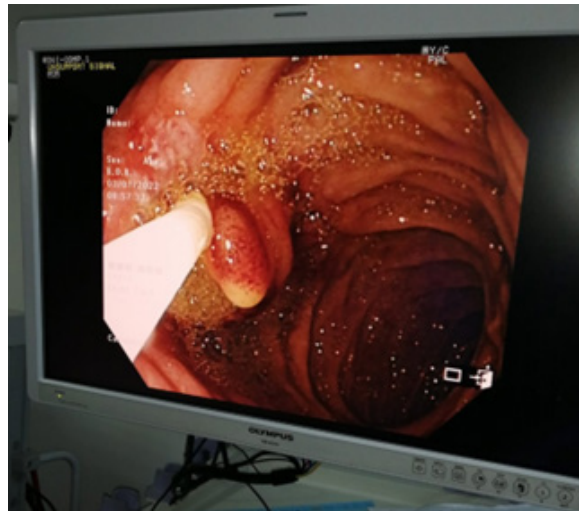

Figure 4. Endoscopic image of duodenal polypectomy.

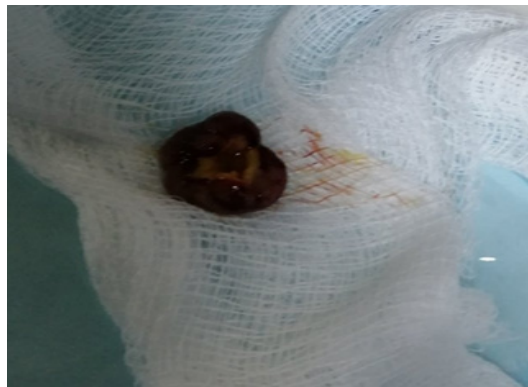


Figure 5. Polyp retrieved.

REFERENCES

1. Jung SH, Chung WC, Kim EJ, et al. Evaluation of non-ampullary duodenal polyps: comparison of non-neoplastic and neoplastic lesions. *World J. Gastroenterol.* 2010; **16**: 5474– 5480.
2. Mitsuishi T, Hamatani S, Hirooka S et al. Clinicopathological characteristics of duodenal epithelial neoplasms: focus on tumors with a gastric mucin phenotype (pyloric gland-type tumors). *PLoS ONE* 2017; **12**: 0174985.
3. Remmele W, Hartmann W, von der Laden U, et al. Three types of duodenal polyps: mucosal cysts, focal foveolar hyperplasia, and hyperplastic polyp originating from islands of the gastric mucosa. *Dig. Dis. Sci.* 1989; **34**: 1468– 1472.
4. Rosty C, Buchanan DD, Walters RJ, et al. Hyperplastic polyp of the duodenum: a report of 9 cases with immunohistochemical and molecular findings. *Hum. Pathol.* 2011; **42**: 1953– 1959.
5. Clinical Issues Committee of the American Society for Metabolic and Bariatric Surgery. Updated position statement on laparoscopic sleeve gastrectomy as a bariatric procedure. *Surg Obes Relat Dis* 2010; **6**: 1–5
6. Casella G, Soricelli E, Rizzello M, et al. Nonsurgical treatment of staple line leaks after laparoscopic sleeve gastrectomy. *Obes Surg* 2009; **19**: 821–826
7. Serra C, Baltasar A, Andreo L, et al. Treatment of gastric leaks with coated self-expanding stents after sleeve gastrectomy. *Obes Surg* 2007; **17**: 866–872
8. Puli SR, Spofford IS, Thompson CC. Use of self-expandable stents to treat bariatric surgery leaks: a systematic review and meta-analysis. *Gastrointest Endosc* 2012; **75**: 287–293
9. <http://www.taewoongmedical.com/data/bbsData/16135494902.pdf>